

USE OF RIGID, FIXED BRAIN RETRACTORS IS HARMFUL FOR THE BRAIN

Naveed Khan¹, Muhammad Saad Usmani², Shua Nasir³, Lal Shehbaz⁴, Alvia Saad⁵

¹Department of Neurosurgery, Ziauddin University & Hospital & Consultant neurosurgeon National Medical Center Karachi, Pakistan, ²Department of Anatomy, Liaquat College of Medicine & Dentistry & Darul Sehat Hospital, Karachi, Pakistan, ^{3,4}Department of Emergency Medicine, Ziauddin University & Hospital, Karachi Pakistan, ⁵Department of Medicine, Registrar, Patel Hospital Emergency, Karachi, Pakistan

Correspondence:

Dr Alvia Saad

Department of
Medicine, Registrar,
Patel Hospital
Emergency, Karachi,
Pakistan

Email: alvi-asaad@gmail.com

DOI:

10.38106/LMRJ.2022.4.3-07

Received: 28.06.2022

Accepted: 13. 09.2022

Published: 30. 09.2022

ABSTRACT

While operating upon the brain, deep seated lesions need to be approached by using retractor's system, due to the soft and gelatinous nature of the brain. Using a conventional rigid, fixed retractor system for brain retraction appears harmful. As an alternative Thudicam Nasal Speculum (TNS) retractors can be used. This study was aimed to explore the outcome of TNS retractors in brain surgery. The cross-sectional study was conducted at Ziauddin University hospital north campus and National Medical Center Defense, Karachi, Pakistan, during a period between August 2019 to March 2020. A total of 60 patients were included (42 males and 18 females), with a median age of 25 years. In all these cases intra-cranial hematoma were removed with unremarkable damage, in aneurysm clipping it was found useful, without damaging adjacent areas and extraction of brain tumors was found to be very easy and non-damaging to the surrounding brain tissue. Patients had a follow-up period of about 03 months and contusion, ischemia or brain edema was not present in any patient. Only one patient died during second month after surgery due to Ischemic stroke of contra-lateral MCA. The study concludes that using TNS retractors was very helpful and non-damaging to the brain.

Key Words: Brain Retractors, Brain injury, Neurosurgical procedures

INTRODUCTION

The iatrogenic injuries caused by brain retractors are consequences of neurosurgical procedures, however, the advent of newer retractors has improved surgeons comfort in the visibility of the lesions, procedural ease and minimal brain injury (1-5). Deep brain lesions such as tumors, aneurysms, intra-cranial hematoma and intraventricular tumors, are difficult to approach without retraction, and at the same time if microscope or endoscope is to be used it becomes even tougher to avoid any damage to the falling brain(1,5, 6). A study by Butt et al has found a 33.33% to 66.66% rate of brain edema observed in excision to debulking procedures of brain tumors (7) causing further hindrance in approaching the operating field(3). In situations like these, use of rigid, fixed retractor can cause brain contusion or ischemia to the brain, sometimes postoperative bleeding and hematoma (6.7%) may occur under the retracted area of the brain (8). Moreover, glare of light from the rigid fixed retractor while using headlight is another disadvantage which one has to overcome by certain adaptations (4).

Fixed rigid retractor systems are very expensive leading to further rise in the surgery cost. In contrast, the use of Thudicam Nasal Speculum (TNS) retractors is far safer, due to its low weight, soft prongs and malleable blades, which reduces the risk of post-operative bleeding, infarct, contusion or edema. The TNS retractors are available in different sizes. Due to these sizes, lesions at different depths become easily accessible without any harm to the brain and with a smaller cortisectomy (10). Shiparo et al in a review of current studies, found that evacuation of hematoma and total resections and subtotal resections of tumors, the rate of complications was 2.8% at short term postoperative period(6). Another study by Lim et al has found good surgical outcomes with using brain retractors in tumor removal (10-12). However, there was limited literature available for different procedures. Therefore, this study was conducted to explore post-operative outcome following use of TNS retractors for different brain procedures.

METHODS

This cross-sectional study was conducted on 60 patients without any age or gender restriction. The cases were prospectively studied and followed-up. The study was conducted at Zia ud Din University Hospital north campus and National Medical Center Defense, Karachi, Pakistan during a period of eight months from August 2019 to March 2020. Before surgery, a written informed consent was taken regarding surgical technique from patients (GCS 15/15) or their relatives. Different types of TNS retractors were used for different depths of lesions, for deep lesions small modifications were made in the soft and malleable long blades of TNS retractors, the lower ends were bent so the blades became more widened for the extractions of lesions, without causing any damage to the normal surrounding brain tissue. All patients had Computed Tomography (CT) scan of the head postoperatively (Figure 1).

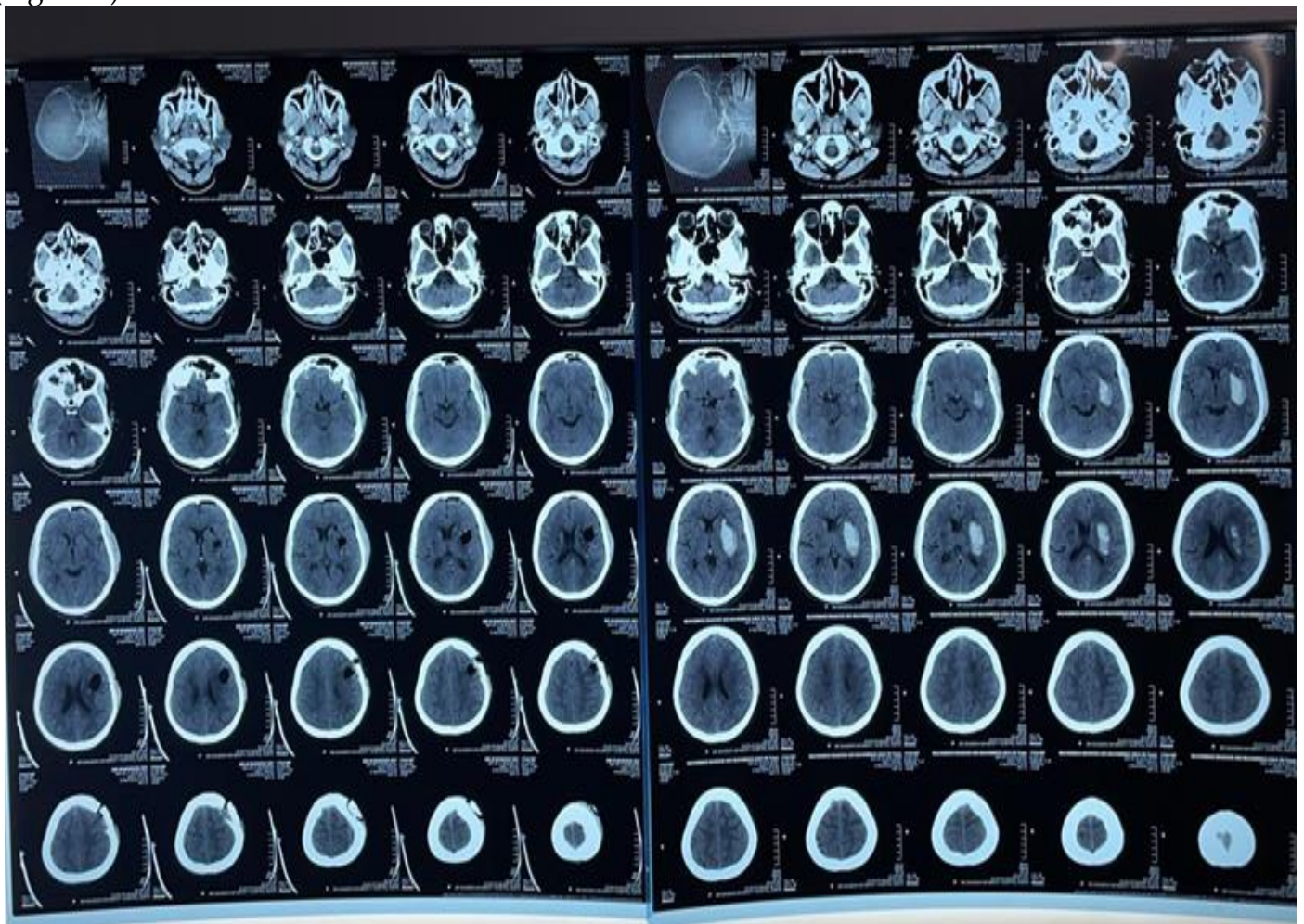


Figure 1. Computed Tomography scan of the patient after surgery

TECHNIQUE:

All surgical procedures were performed under general anesthesia using standard sterilization techniques, skin incisions were marked using standard brain mapping technique and linear, rounded or horse shoe-shaped incisions were made according to the needs. Osteoblastic or Osteoclastic bone flaps raised, dura was opened by linear incision, after a small cortisectomy lesion was identified and depth was measured with the help of Codman Dandy ventricular needle. Depending on the depths of the lesions, different sizes of TNS retractors were used. TNS retractors were very helpful using headlight, microscope, or endoscope. No glare of light, no brain trauma, even at edematous brain were observed.

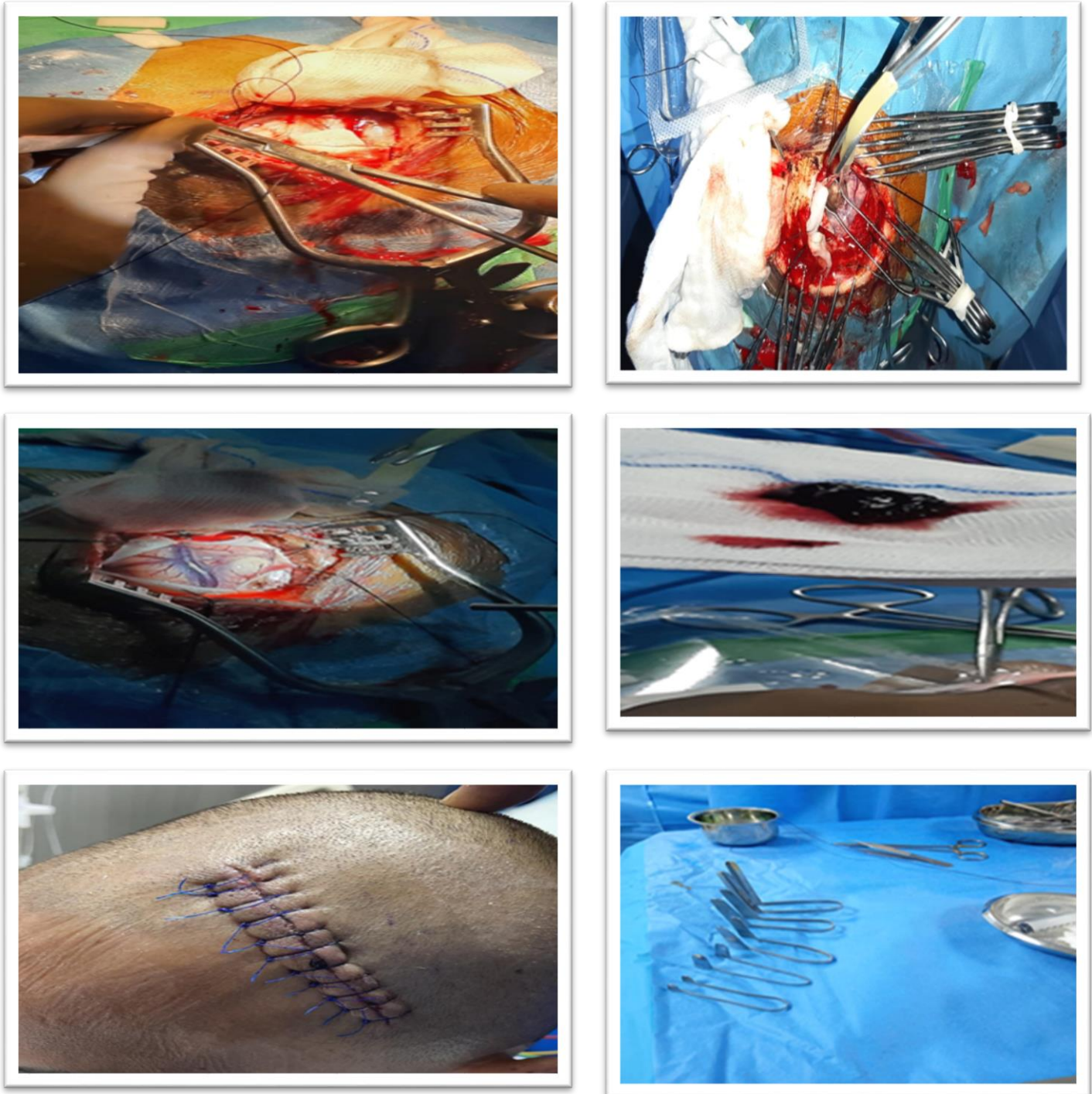


Figure 2. Surgical procedure showing use of retractors

RESULTS

There were 60 patients with a median age of 25 years, where 17.5% were below or equal to 10 years of age, 47.5% were between 11 to 30 years, and 35% were above 30 years of age. There were 42 males and 18 females. All surgical procedures were performed without any immediate complications. In cases of intra-cranial bleeding almost 100% of hematoma were removed, aneurysm clipping was done without any event per operatively, extraction of brain tumors was also done without causing any damage to the surrounding normal brain tissue. Median follow-up of the patients was three months, no remarkable post-operative contusion, ischemia or brain edema were reported. One patient died of ischemic stroke of contralateral MCA second month post-operatively.

DISCUSSION

Iatrogenic brain retraction injuries occur in around 10% of major procedures of cranial tumors and 5% of intracerebral aneurysms as previously reported (11-15). These injuries may range from mild edema to severe edema even contributing to mortality. However, with advent of newer techniques and modern retractors this can be minimized (16-20). In our study, with the use of TNS retractors there were almost no postoperative complications.

In some difficult surgical lesions there is a need of rigid retractors i.e. 5.7% in the study reported by Nazim et al (15). Rigid fixed retractors hide the normal anatomy, moreover in longer procedures like resection of brain tumors or clipping an aneurysm, prolonged application of rigid fixed brain retractors can cause contusion, ischemia or edema to the surrounding brain tissue that may result in irreversible brain damage. The Cochrane Systematic Review however, has concluded that there is no significant difference in the complications rate by using different types of retractors(3). On the contrary, the use of TNS retractors was found to be very helpful and non-damaging to the brain. TNS retractors can be applied in all those procedures involving headlight, microscope or telescope. Safronova et al found favourable postoperative results in deep brain injuries and tumor excision by combining microsurgical technique, craniotomy and retractors of tubular variety (11). Deep or shallow lesions are easily resectable. A small incision of 2 to 3 mm is needed on the cortex of the normal brain to reach the deep lesions. According to the depth of the lesions, different sizes of TNS retractors were available, the prongs and blades of TNS retractors were found pulsating with the brain leaving no contusion, edema or ischemia to the surrounding normal brain tissue. The simple TNS retractors have made the surgical approach to deep brain lesions of the brain, very safe, cheap and time-saving. The study has shown remarkable results with almost no complications. However, small sample size and short follow-up of the patients are considered as the limitations of the study. Surgical expertise of the operating team can also influence results in this kind of studies. Nevertheless prospective nature of this study is considered as the strength of the study.

CONCLUSION

In our study TNS retractors were found to be very helpful and non-damaging to the brain and can be applied in all those procedures involving headlight, microscope or telescope. Deep or shallow lesions are easily resectable. However, large cohort studies are required to confirm long-term effects.

ETHICAL CONSIDERATION

The study was approved by local ethics committee, all patients or their relatives provided informed consent before the surgical procedure. The identity of the patients was not disclosed.

CONFLICT OF INTEREST

Authors declare no conflict of interest

FUNDING

This was an observational study, no funding required.

REFERENCES

1. Rao D, Le RT, Fiester P, Patel J, Rahmathulla G. An illustrative review of common modern craniotomies 2020 Dec 10. *J Clin Imaging Sci.* 2020 Dec 10;10:81. doi: 10.25259/JCIS_176_2020. eCollection 2020.
2. Zammar SG, Cappelli J, Zacharia BE. Utility of tubular retractors augmented with intraoperative ultrasound in the resection of deep-seated brain lesions: technical note. *Cureus.* 2019;19;11(3):e4272. doi: 10.7759/cureus.4272.
3. Echeverry N, Mansour S, MacKinnon G, Jaraki J, Shapiro S, Snelling B. Intracranial tubular retractor systems: a comparison and review of the literature of the BrainPath, Vycor, and METRx tubular retractors in the management of deep brain lesions. *World Neurosurg* 2020;143:134-146.
4. Zagzoog N, Reddy K. Use of minimally invasive tubular retractors for foramen magnum decompression of chiari malformation: a technical note and case series. *World Neurosurg* 2019;128:248-53.
5. Mampre D, Bechtle A, Chaichana KL. Minimally invasive resection of intra-axial posterior fossa tumors using tubular retractors. *World Neurosurgery* 2018;119:e1016-e1020.
6. Shapiro SZ, Sabacinski KA, Mansour SA, Echeverry NB, Shah SS, Stein AA, Snelling BM. Use of Vycor Tubular Retractors in the Management of Deep Brain Lesions: A Review of Current Studies. *World Neurosurg.* 2020;133:283-290. doi: 10.1016/j.wneu.2019.08.217. Epub 2019 Sep 7.
7. Butt B, Shiekh MM, Nabila, Anwar H, Chudary MA, Butt RM. Six months analysis of posterior fossa surgery in neurosurgery unit-I, Punjab Institute of Neurosciences (PINS). *Pak J Neuro Surg* 2018;22(1):7-16.
8. Sharafat S, Khan Z, Brohi SR, Ali M, Azam F. Spectrum of posterior fossa lesions: experience at tertiary care unit. *Pak J Neuro Surg* 2019;23(1):2-6
9. Lim J, Sung KS, Hwang SJ, Chun DH, Cho KG. Tumor retractor: a simple and novel instrument for brain tumor surgery. *World J Surg Oncol.* 2020;13;18(1):37. doi: 10.1186/s12957-020-1800-8.
10. Eichberg DG, Buttrick S, Brusko GD, Ivan M, Starke RM, Komotar RJ. Use of tubular retractor for resection of deep-seated cerebral tumors and colloid cysts: single surgeon experience and review of the literature. *World Neurosurg.* 2018;112:e50–60.
11. Safronova E.I., Kushel Yu.V. Experience in the use of tubular retractors in transcranial surgery of intraaxial brain tumors in children. *Journal "Issues of Neurosurgery" named after N.N. Burdenko.* 2022;86(2):15-24.
12. Mansour S, Echeverry N, Shapiro S, Snelling B. Literature Review the Use of BrainPath Tubular Retractors in the Management of Deep Brain Lesions: A Review of Current Studies. *World Neurosurgery.* 2020;134:155-163. <https://doi.org/10.1016/j.wneu.2019.08.218>
13. Almubarak AO, Alobaid A, Qoqandi O, Bafaquh M. Minimally invasive brain port approach for accessing deep-seated lesions using simple syringe. *World Neurosurgery.* 2018;117:54-61. <https://doi.org/10.1016/j.wneu.2018.05.236>
14. Jackson C, Ehresman J, Vivas-Buitrago T, Bettegowda C, Olivi A, QuinonesHinojosa A, et al. Retractorless surgery: strokes, edema, and gliosis outcomes following skull base surgery. *J Neurol Surg B Skull Base.* 2018;79(S 01):S1–S188. <https://doi.org/10.1055/s-0038-1633350>.
15. Nazim WM, Elborady MA. Retractorless brain surgery:technical considerations. *The Egyptian J Neurolog Psyc Neurosurg* 2021;57:98 <https://doi.org/10.1186/s41983-021-00329-w>.

16. Kretschmer T, Heinen C, Schmidt T. Retractorless surgery of vascular lesions. In: July J, Wahjoepramono EJ, editors. *Neurovascular Surgery: Surgical approaches for neurovascular diseases*. Springer Open; 2019. p.255–267.
17. Piazza A, Ricciardi L, Trungu S, Forcato S, Alessandro di Bartolomeo, Scerrati A, et al. The lone star retractor system in neurosurgery. *World Neurosurg* 2021;153:36-40.
18. Prajapati AK, Vilanilam GC, Vayalappil MC. Development and evaluation of expandable brain retractor with tunable expansion ratio. *Trends in Biomaterials and Artificial Organs* 2022;36(1):21-26.
19. Toyota S, Kumagai T, Goto T, Mori K, Taki T. Utility of the lone star retractor system in microsurgical carotid endarterectomy. *World Neurosurg*. 2017;101:509–13.
20. Uluc K, Cikla U, Morkan DB, Sirin A, Ahmed AS, Swanson K, Baskaya MK. Minimizing retraction by pia-arachnoidal 10-0 sutures in intrasulcal dissection. *Oper Neurosurg (Hagerstown)*. 2018;15:10–4.