

RENAL VASCULAR DISPARITIES AMONG KIDNEY DONORS PRESENTED AT RENAL TRANSPLANT UNIT- A SINGLE CENTRE STUDY

Naranjan Lal¹, Rashid Bin Hamid¹, Muhammad Tassaduq Khan¹, Laraib Khan¹

Renal Transplant Unit, Department of Surgery, Dow University Hospital, Dow University of Health Sciences, Karachi, Pakistan

Correspondence:

Naranjan Lal

Assistant Professor

Renal Transplant Unit,

Dow University of

Health Sciences, Paki-

stan

Email: naran-

jan.lal@duhs.edu.pk

DOI:

10.38106/LMRJ.2023.5.3-05

Received: 30.07.2023

Accepted: 22. 09.2023

Published: 30. 09.2023

ABSTRACT

Renal vasculature has been reported to show anatomical variations, which may lead to surgical complications. The pattern of renal vascular variations in Pakistani population is not well reported. Thus, this study was designed to assess the renal vascularity among kidney donors and correlate with age, gender and site of vessels. A total of 223 healthy volunteers underwent evaluation for kidney donation at the Radiology Department, DOW University Hospital, Karachi, Pakistan from January 2020 to July 2022 were included. The assessment of renal vasculature was done on computed (CT) angiogram. Renal vascular variations were found in 112 (50.2%), 59.8% were seen in males and 40.2% in females. On right side 50% vascular anomalies were found followed by left side with 27% and 22% on both sides. The arterial variants included accessory renal artery seen in 76 (67.8%) individuals, out of which 13.2% had in upper polar, 26.3% in hilum, 36.8% in lower polar, while 23.7% of early branching was observed. Ten retro-aortic, fourteen accessory renal veins and six bifurcation renal veins, along with six early branching renal veins, were present. Patient who received donor nephrectomy, the outcomes of the operation were completely consistent with the results of the CTA. According to this study, Pakistani population have differences in their renal venous and arterial anatomy, which can significantly influence surgical procedures.

Key Words: Emergency obstetric hysterectomy, Depression, young women

INTRODUCTION

The renal vessels have been reported for exhibiting a wide variety of variances from cadaveric imaging studies. Due to the increasing frequency of kidney disease, transplant surgeons, nephrologists and radiologists are intensely interested in renal vascular variations. With the development of renal transplantation, variation in renal vascular anatomy has become more significant since it is critical in determining which kidney (left or right) to be transplanted(1). Variations in the arteries and/or veins of the kidneys are frequently observed in kidney donors (~ 48% and 53%). These differences include perihilar bifurcation (early branching), extra renal arteries, and unusual renal artery branching. Multiple renal veins, retro aortic, bifurcation, and early branching renal veins are examples of venous variant(2).

End-stage renal disease (ESRD) is becoming more common across the globe, which presents a serious problem for the world's health care systems. The preferred course of treatment for ESRD is kidney transplantation, which is anticipated to dramatically improve a patient's quality of life. The most successful way for treating end-stage renal illness is kidney transplantation(3). The use of living donor kidney transplantation is rising as a result of a lack of cadaveric organs. Preoperative radiological examination of living donors is essential since the quality of the graft organ is what determines whether organ transplantation is successful. This necessitates precise imaging of the potential donor's renovascular systems, collecting system, and renal architecture. The renal vasculature can be quickly, safely, minimally invasively, and generally assessed before surgery using spiral computed tomography angiography (CTA). To prevent unintended consequences like venous and/or arterial injury during donor nephrectomy, it is especially crucial to demonstrate renal artery variations accurately and in detail during the preoperative examination(4). To ensure the safety of the donor, Glomerular filtration rate (GFR) and albuminuria are two essential factors in determining the probability of long-term negative effects following donation. Both are used to identify the existence of renal disease. Urinary clearance

of an ideal filtration marker is the "gold standard" for determining GFR, and albuminuria is typically determined from untimed "spot" urine samples using the albumin to creatinine ratio(5). Every living donor should undergo a thorough medical evaluation, which should include a thorough medical history, physical examination, blood and urine screening tests, an electrocardiogram, a chest X-ray, and imaging analysis of the kidney anatomy and its associated vasculature. The most prevalent application of CT angiogram, which has been shown to be a precise, safe, and economical procedure, is for the anatomical assessment of the renal donor. In some facilities, certain living kidney donor patients get MRI/MRA. Less frequently is ultrasound used during kidney examinations for living donors(6).

COMPUTED TOMOGRAPHY ANGIOGRAPHY (CTA):

A standard CTA procedure for evaluating Renal Healthy donor can undergo CTA imaging using a 4-phase CT image acquisition methodology. During first phase a non-contrast image acquisition is done followed by the arterial phase and nephron graphic phase, and finally excretory phase which is also known as pyelographic phase(7).

Acquiring Non-Contrast Images

This is the best phase to determine whether kidney stones or calcifications are present. However, given that the donor are healthy volunteers the arterial phase is considered to be sufficient for detecting kidney stones. In many centers this phase is not highly recommended. On CT scans, this could, however, lead to an increase in false-positive "stone" detection.

Arterial Phase CTA Image Acquisition

Automated bolus monitoring can be used in CTA for renal donors, much like it is in conventional CT angiography investigations to evaluate abdominal artery anatomy. An injection rate of 4 to 5 mL/s can be used to provide a nonionic contrast agent with a concentration of 300 or 370 mg iodine/mL. Depending on the iodine concentration, the maximum dose for the contrast should be 100 or 120 ml. The diaphragm dome and the distal part of the common iliac arteries, or the iliac crest, should be the best anatomic coverage for CTA. Another choice for getting the CTA is to slightly postpone the arterial phase image acquisition by 25–30 seconds. Some venous structures, such as the adrenal and gonadal veins, can be assessed using delayed arterial phase imaging.

Nephrographic Phase Image Acquisition

This phase is used to evaluate renal parenchymal status, where any renal mass can be excluded. This phase portrays renal venous architecture, which also includes smaller veins to the adrenal glands.

Excretory Phase Image Acquisition

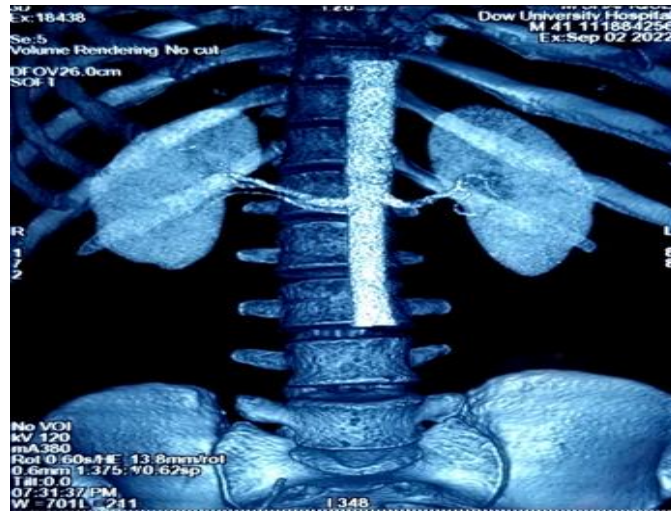This phase is taken between 4 to 8 minutes after contrast injection. During this phase whole collecting system is assessed for any pathology. In some centers only scout image is taken to avoid longer radiation exposure. Though, taking only scout image may pose a risk of missing any urothelial mass in a donor kidney.

For patients with end stage renal disease kidney transplantation is the life-saving procedure. The detailed assessment of the donor kidney before transplantation is the essential component and greatly influences success of the transplantation. The assessment also includes renal vascular assessment of the donor in order to avoid any surgical complications. Currently CT angiography is the gold standard method.

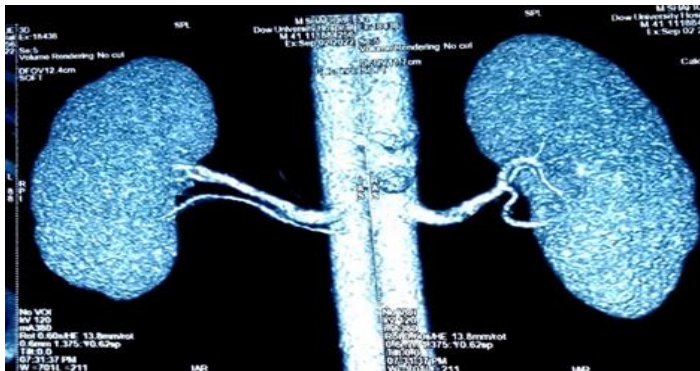
There is always a chance of finding anatomical variations in humans including renal vasculature. This is particularly important in transplant procedures. There are a number of cadaveric reports where renal anomalies have been reported. However, there is limited literature available including living donors. Thus this study was designed to assess CT angiography of the living donor assessed for renal vasculature.

METHODS

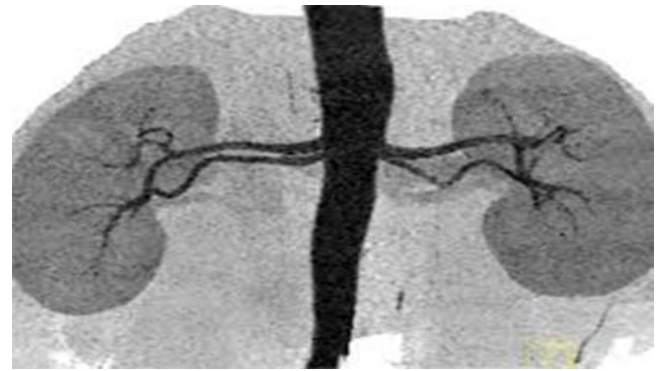
The current study was carried out at the Renal Transplant Unit of the DOW University of Health Sciences' (OJHA Campus), Karachi, Pakistan. This was a retrospective cross-sectional study based on an institution and a review of old records from transplant unit. All kidney donors who had donor nephrectomy between 2020 and 2022 were the subject of the study. 24 patients' records from 247 kidney donor were excluded from this study because they had CT angiography done from other hospital.



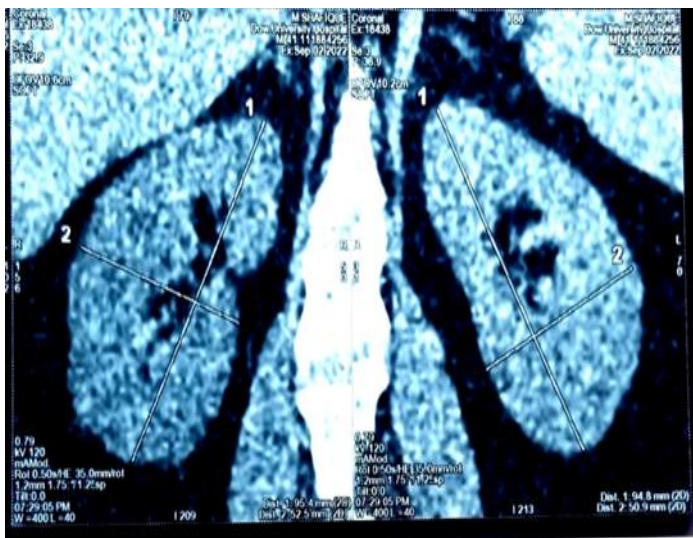
a



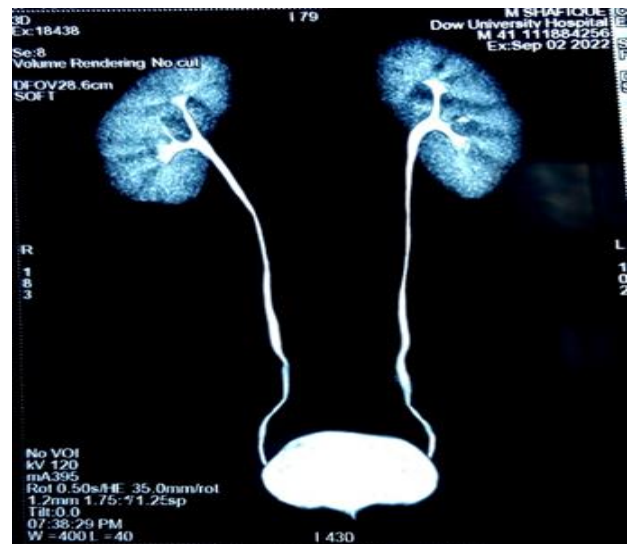
B



c



d



e

Figure 1. CT angiograms of different phases: a: Arterial Phase, b: Arteria Phase, two arteries on right side c: Arterial phase, bilateral renal arteries d: Nephrographic phase e: Excretory phase

This study involved a total of 223 kidney donors. A standardized checklist was used to capture information about each kidney donor's age, sex, and description of the renal vascular anatomic reports made by radiolo-

gists (CT Angiography reading) and transplant surgeons in the centre. After a thorough examination of pertinent literature and comparable research, a data collection method was created to ensure the quality of the collected data.

In this study, we describe the pattern of vessels as follows: A major renal artery that has branched was referred to as an early branching renal artery. At the left side renal vein that runs posterior to the abdominal aorta between the aorta and empties into the inferior vena cava is known as the retro aortic renal vein. The left renal vein's division into its anterior and posterior limbs is known as the bifurcation of the renal vein.

Statistical analysis

After being coded, cleaned up, and entered into Epi-data version 4.4, all the collected data was exported to SPSS version 20 for analysis. Calculated descriptive statistics included frequencies and percentages. With regard to the gender and laterality, the information on the renal vascular structure was assessed. For categorical data, the chi-square test was used, and $p\text{-value} < 0.05$ was regarded as statistically significant.

RESULTS

Basic demographic features of kidney donors

A total of 223 individuals were included in this study, of which 103 (46.2%) were men and 120 (53.8%) were women kidney donors. The age of the donors ranged from 18 to 65 years, with a mean age of 34.36 years (\pm SD 10.02). The majority of the donors (~50.8%) were between the age of 20 and 30 years. However, it was significantly correlated with vasculature variation ($p\text{-value}=0.630$).

A total of 112 kidney donors showed vascular variation including 30.0% of male donors and 20.17% of female donors. Males substantially outnumbered than females in terms of the proportion of renal vascular alterations but it was not significantly correlate with gender ($p\text{-value}= 0.38$).

Pre-operative CT angiograms were performed of the donors to evaluate the renal vascular architecture. A statistically significant correlation between vascular variations and laterality was observed ($p\text{-value} < 0.001$). A summary of vascular variations is presented in Table 1, which were more common at right side as compared to left side (25.1% versus 13.9% respectively) and variation on both sides was observed is 11.2% (Figure 2).

kidney donors' renal vascular variations

Table 2 showed number of vessels among gender. At right side double artery was more common among males than females (31.25% versus 13.39% respectively), while double vein were more common among females than males (14.3% versus 11.6% respectively). On left side double artery was more common among males than females (25.8% versus 15.2% respectively) while double vein was not common among females and only small proportion of males. Vasculature variation did not statistically correlate with laterality and number of vessels.

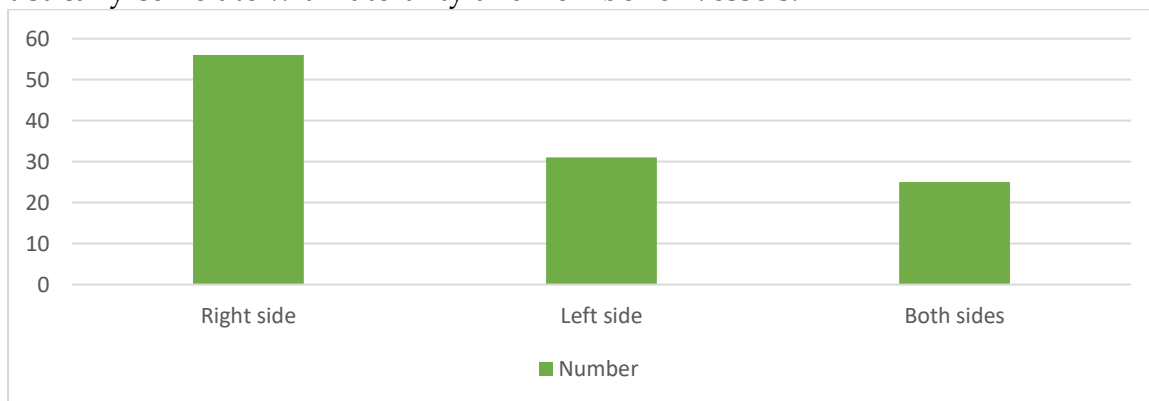


Figure 2. Demographic characteristics of kidney donors with vascular anatomy

Table 3 showed arterial and venous variations. The accessory renal artery was more commonly originated from lower pole (36.8%) while 23.7% early branching was observed in arterial variation. In venous variations, 16.7% showed accessory renal vein in males and 22.2% among females. Retro aortic veins (13.9%) and early branching (8.3%) are equally observed among males and females while bifurcation variation (16.7%) were identified only among females.

Table 1. Number of vessels in Kidney donors- males versus female donors

Number of vessels	Gender		Total (n=112)
	Male (n=67, 59.8%)	Female (n=45, 40.2%)	
Right Renal Artery			
Single	31(27.6)	28(25.0)	59(52.7)
Double	35(31.2)	15(13.4)	50(44.6)
Triple	1(0.9)	2(1.8)	3(2.7)
Right Renal Vein			
Single	53(47.3)	29(25.9)	82(73.2)
Double	13(11.6)	16(14.3)	29(25.9)
Triple	0(0.0)	1(0.9)	1(0.9)
Left Renal Artery			
Single	36(32.1)	26(23.2)	62(55.3)
Double	29(25.8)	17(15.2)	46(41.1)
Triple	3(2.7)	1(0.9)	4(3.6)
Left Renal Vein			
Single	66(58.9)	45(40.2)	111(99.1)
Double	1(0.9)	0(0.00)	1(0.9)
Triple	0(0.0)	0(0.0)	0(0.0)

Table 3: Presentation of vascular variation among kidney donors

Type of variation	Gender		Total
	Male	Female	
Arterial			
Upper Polar	6(7.9)	4(5.3)	10(13.2)
Hilar	8(10.5)	12(15.8)	20(26.3)
Lower pole	20(26.3)	8(10.5)	28(36.8)
Early branching	12(15.8)	6(7.9)	18(23.7)
Venous variation			
Accessory vein	6(16.7)	8(22.2)	14(38.9)
Retro-aortic vein	5(13.9)	5(13.9)	10(27.8)
Early branching	3(8.3)	3(8.3)	6(16.6)
Bifurcation	0(0)	6(16.7)	6(16.7)

DISCUSSION

The most effective form of treatment for ESRD is a kidney transplant. It is technically simpler to transplant kidneys with one renal artery than kidneys with several renal arteries. Furthermore, compared to kidney transplantation involving transplantation of kidneys with more than one renal artery, the postoperative rates

of complication and kidney loss are lower when transplanting kidneys with just one renal artery(11,12). For a successful graft nephrectomy, the surgeon must have precise preoperative knowledge of the donor's renal vasculature in order to lower the risk of vascular injury and decrease the time of ischemia. Renal CT angiogram is the most popular technique for assessing the donor's renal arteries. The kidney with a less complex vascular architecture is removed if both kidneys are healthy. Since the left kidney has a larger renal vein and is surgically simpler to remove, it is favoured for laparoscopic living donor nephrectomy(13–15). Right donor nephrectomy is preferred in several situations, such as complex left vascular anatomy or many auxiliary arteries. Because of this, CTA is crucial in selecting the best donor kidney based on the vasculature. According to earlier research, CTA can accurately identify donor vessels 95% to 100% of the time(12). All CTA results in our investigation were in agreement with the results of the operations on the harvested kidneys. Up to one-third of the general population can have accessory renal arteries, which are the most prevalent and clinically significant renal arterial variants. However, there is little chance that a kidney donor will have several renal arteries in both kidneys(16).

This study has shown a considerable number of healthy volunteers presenting with renal vascular variation. As reported previously there was predominance of males in having these variations (17). In this study 50.2% population had reported higher rate of renal vascular variation while 43.2% of renal variation reported in Iranian study conducted by Famurewa et al., in Nigerians reported rate was 50 %, while in Indians it was 59.5% (2,18). It can be inferred that the prevalence of renal vascular variations is extremely divergent in different populations and it is may be due to genetic differences across the populations. The frequency of anatomic alterations in the renal arteries vary among various ethnic and racial groups in the general population. Up to one-third of the normal population may have accessory renal arteries, which are the most prevalent and clinically significant renal arterial variation(19). However, it has been found that there is a low likelihood that a kidney donor will have more than one accessory renal artery in both kidneys(20). In the present study arterial and venous variations were more common on the right side, dissimilarly dominance of arterial variations in the left side were observed by Cinar et al(19). To the best of our knowledge, this study—in which CTA was utilized to assess renal arteries in almost 223 kidney transplantations—is the largest series in the literature. The fact that 67.9% of the donors had renal arteries visible on CTA is a significant finding in this dataset. This discovery, in our opinion, is extremely helpful in terms of giving the surgical team performing the donor nephrectomy a preliminary concept. It is well documented that the incidence of accessory renal arteries varies widely with population, ranging from 11.4 % in Kenyans to 59.5 % in Indians(21). Variation of renal artery were classified on the basis of their point of entry to the kidney, and the lower polar arteries were found to be the commonest (36.8%). This is due to the fact that kidneys ascend from the pelvic region during embryonic time; the most likely accessory renal arteries which fail to regress and persist will remain in the lower pole of the kidney(11, 22). Early branching of renal artery have immense importance during the transplantation, as failure of anastomosing them might lead to necrosis of a segment of the kidney and may require a surgeon to discard the graft(8). Moreover, Lower polar arteries may cause obstruction at the uretero-pelvic junction leading to hydronephrosis. During the renal transplantation, renal artery incision should be done 1.5–2 cm distal from the aortic origin to provide an easier haemorrhage control and to make anastomosis suitable. As a result, determining any possible early branching of the main renal artery is critical. The 23.7 % of early branching of the main renal artery reported in the present study. In accordance with previous studies, this study confirms the most frequent renal vein variation is accessory renal veins (38.9 %)(4). In angiographic and post-mortem studies, the prevalence of multiple renal veins was reported to be 11–28 %(23). Retro aortic left renal vein was found in eight donors, which is consistent with a previously reported study. Retro aortic left renal veins may have a high number of lumbar retroperitoneal tributaries, forming complex retro aortic systems, which can be easily injured during surgical dissection(23). This study excluded 24 kidney donors who had CT Angiogram from outside the DOW hospital. If all kidney donor candidates had CT angiogram from other hospital, the chance of finding a more complex variant vasculature would increase.

CONCLUSION

This study concluded that Pakistani population have differences in their renal venous and arterial anatomy. The planning of surgical procedures can be significantly influenced by these variations and risk per-operative complications. To avoid diagnostic mistakes and to optimize surgical techniques to prevent undesired postsurgical morbidities, radiologists and surgeons need to be aware of all potential variants.

Conflict of interest:

Authors declare no conflict of interest

Funding source:

The study did not receive any external funding

Ethical Approval:

The data was retrospective analysis of hospital record, did not require ethical approval. At the time of transplant informed consent, patients and donors also consent for utilization of their information for research purpose.

REFERENCES

1. Gebremickael A, Afework M, Wondmagegn H, Bekele M. Renal vascular variations among kidney donors presented at the national kidney transplantation center, Addis Ababa, Ethiopia. *Transl Res Anat* . 2021 Nov;25:100145.
2. Famurewa O, Asaleye C, Ibitoye B, Ayoola O, Aderibigbe A, Badmus T. Variations of renal vascular anatomy in a Nigerian population: A computerized tomography study. *Niger J Clin Pract*. 2018;21(7):840.
3. Sarier M, Callioglu M, Yuksel Y, Duman E, Emek M, Usta SS. Evaluation of the Renal Arteries of 2,144 Living Kidney Donors Using Computed Tomography Angiography and Comparison with Intraoperative Findings. *Urol Int* . 2020;104(7–8):637–40.
4. Aghayev A, Gupta S, Dabiri BE, Steigner ML. Vascular imaging in renal donors. *Cardiovasc Diagn Ther* . 2019 Aug;9(S1):S116–30.
5. Inker LA, Huang N, Levey AS. Strategies for Assessing GFR and Albuminuria in the Living Kidney Donor Evaluation. *Curr Transplant Reports*. 2017 Mar 24;4(1):13–23.
6. Ikidag MA, Uysal E. Evaluation of Vascular Structures of Living Donor Kidneys by Multislice Computed Tomography Angiography before Transplant Surgery: Is Arterial Phase Sufficient for Determination of Both Arteries and Veins? *J Belgian Soc Radiol* . 2019 Apr 4;103(1).
7. Steinmetz JD, Bourne RRA, Briant PS, Flaxman SR, Taylor HRB, Jonas JB, et al. Causes of blindness and vision impairment in 2020 and trends over 30 years, and prevalence of avoidable blindness in relation to VISION 2020: the Right to Sight: an analysis for the Global Burden of Disease Study. *Lancet Glob Heal* . 2021 Feb;9(2):e144–60.
8. Hostiuc S, Rusu MC, Negoii I, Dorobanțu B, Grigoriu M. Anatomical variants of renal veins: A meta-analysis of prevalence. *Sci Rep* . 2019 Jul 25;9(1):10802.
9. Munnusamy K. Variations in Branching Pattern of Renal Artery in Kidney Donors Using CT Angiography. *J Clin DIAGNOSTIC Res* . 2016;
10. Black CK, Termanini KM, Aguirre O, Hawksworth JS, Sosin M. Solid organ transplantation in the 21st century. *Ann Transl Med* . 2018 Oct;6(20):409–409.
11. He B, Hamdorf J. Clinical importance of anatomical variations of renal vasculature during laparoscopic donor nephrectomy. *OA Anat* . 2013 Oct;1(3).
12. Muturi A, Kotecha V, Kanyi S. A retrospective study to assess the evaluation of living related kidney

-
- donors and their outcomes following nephrectomy at Kenyatta National Hospital. *BMC Nephrol* . 2017 Dec 25;18(1):171.
13. Kachlík D, Varga I, Báča V, Musil V. Variant Anatomy and Its Terminology. *Medicina (B Aires)* . 2020 Dec 18;56(12):713.
 14. Han WK, Na JC, Park SY. Low-dose CT angiography using ASiR-V for potential living renal donors: a prospective analysis of image quality and diagnostic accuracy. *Eur Radiol* . 2020 Feb;30(2):798–805.
 15. Mohiuddin M, Mansoor A, Ali M, Hassan N. Analysis of renal artery morphometry in adults: A study conducted by using Multidetector computed Tomography Angiography. *Pakistan J Med Sci* . 2017 Aug 4;33(4).
 16. Khush KK. Donor selection in the modern era. *Ann Cardiothorac Surg* . 2018 Jan;7(1):126–34.
 17. Schold JD. The evolving role of regulatory reporting on patient and donor selection in organ transplantation. *Curr Opin Organ Transplant* . 2020 Apr;25(2):158–62.
 18. Budhiraja V, Rastogi R, Jain V, Bankwar V. Anatomical variations of renal artery and its clinical correlations: A cadaveric study from central India. *J Morphol Sci*. 2013;30(4):228–33.
 19. Çınar C, Türkvatan A. Prevalence of renal vascular variations: Evaluation with MDCT angiography. *Diagn Interv Imaging* . 2016 Sep;97(9):891–7.
 20. Sungura R, Mathenge I, Onyambu C. The CT Angiographic Prevalence of Renal Accessory Arteries in Kenya. *Int J Curr Microbiol Appl Sci*. 2018 Jan 20;7(1):2745–54.
 21. Manipal S. Renal artery variations: a cadaveric study with clinical relevance *ijcrr*. 2013;05(March):154–61.
 22. Bachul PJ, Osuch C, Chang E, Bętkowska-Prokop A, Pasternak A, Szura M, et al. Crossing Anatomic Barriers—Transplantation of a Kidney with 5 Arteries, Duplication of the Pyelocalyceal System, and Double Ureter. *Cell Transplant* . 2017 Oct 21;26(10):1669–72.
 23. Kawamoto S, Montgomery RA, Lawler LP, Horton KM, Fishman EK. Multi-Detector Row CT Evaluation of Living Renal Donors Prior to Laparoscopic Nephrectomy. *RadioGraphics* . 2004 Mar;24(2):453–66.